International Journal of Current Microbiology and Applied Sciences
ISSN: 2319-7706 **Special Issue-1 (2015) pp. 26-28**
http://www.ijcmas.com



Case Study

Pulmonary Tuberculosis in a Cancer Chemotherapy Patient: Experiences and Lessons Learnt

Aparna Sharma* and S.M. Kamil Ashraf

[1]Department of Medicine, J N Medical College, AMU, Aligarh, India
**Corresponding author*

Keywords

Immuno compromised, Pulmonary tuberculosis, Cancer patients, BCG vaccine

A B S T R A C T

Pulmonary tuberculosis (TB) is highly prevalent in the Indian subcontinent. One of the often ignored sources of spread of TB is through hospital acquired infections in already immunocompromised in-hospital patients. Cancer patients are at the highest risk of such exposure. We present a 50 year old male diagnosed as bladder carcinoma receiving regular inpatient cycles of chemotherapy at Radiotherapy ward of JNMC in close vicinity to MDR TB ward. He developed cough and two episodes of hemoptysis. Sputum examination for AFB was positive and CXR revealed infiltrates in upper right lung zone. Identifying Pulmonary TB as a potential source of hospital acquired infections is of prime importance in our setting. Steps to recognise and prevent spread of this disease in cancer patients need frequent review.

Introduction

Pulmonary tuberculosis (TB) is highly prevalent in the Indian subcontinent. One of the often ignored sources of spread of TB is through hospital acquired infections in already immunocompromised in-hospital patients (Ducel, 2012). Cancer patients are at the highest risk of such exposure as they are in an immunodeficient state both due to the malignancy, cytotoxic therapies and malnutrition (Teresa, 2014).

Case Report

We present a 50 year old male diagnosed as a case of bladder carcinoma at JNMC Hospital. He was receiving regular inpatient cycles of chemotherapy at the hospital. Following his fourth cycle of chemotherapy, he developed cough, low grade fever and two episodes of hemoptysis for which he was referred to Medicine OPD at JNMCH. Investigations were ordered and sputum examination for AFB was positive and CXR revealed infiltrates in upper right lung zone (Fig. 1). Haemoglobin of the patient was 8.2gm %. Viral markers and HIV was negative. There was no past history of tuberculosis or intake of anti tubercular drugs. There was also no history of any

contact or any open case of tuberculosis in the family. On investigating the sources of infection it was incidentally recognised that the MDR (Multi Drug Resistant) TB ward lay in close proximity to the chemotherapy section of the hospital which could be an avoidable source of hospital acquired TB in debilitated cancer patients.

Fig.1 Chest X Ray of patient having heterogeneous opacity in right upper lung zone

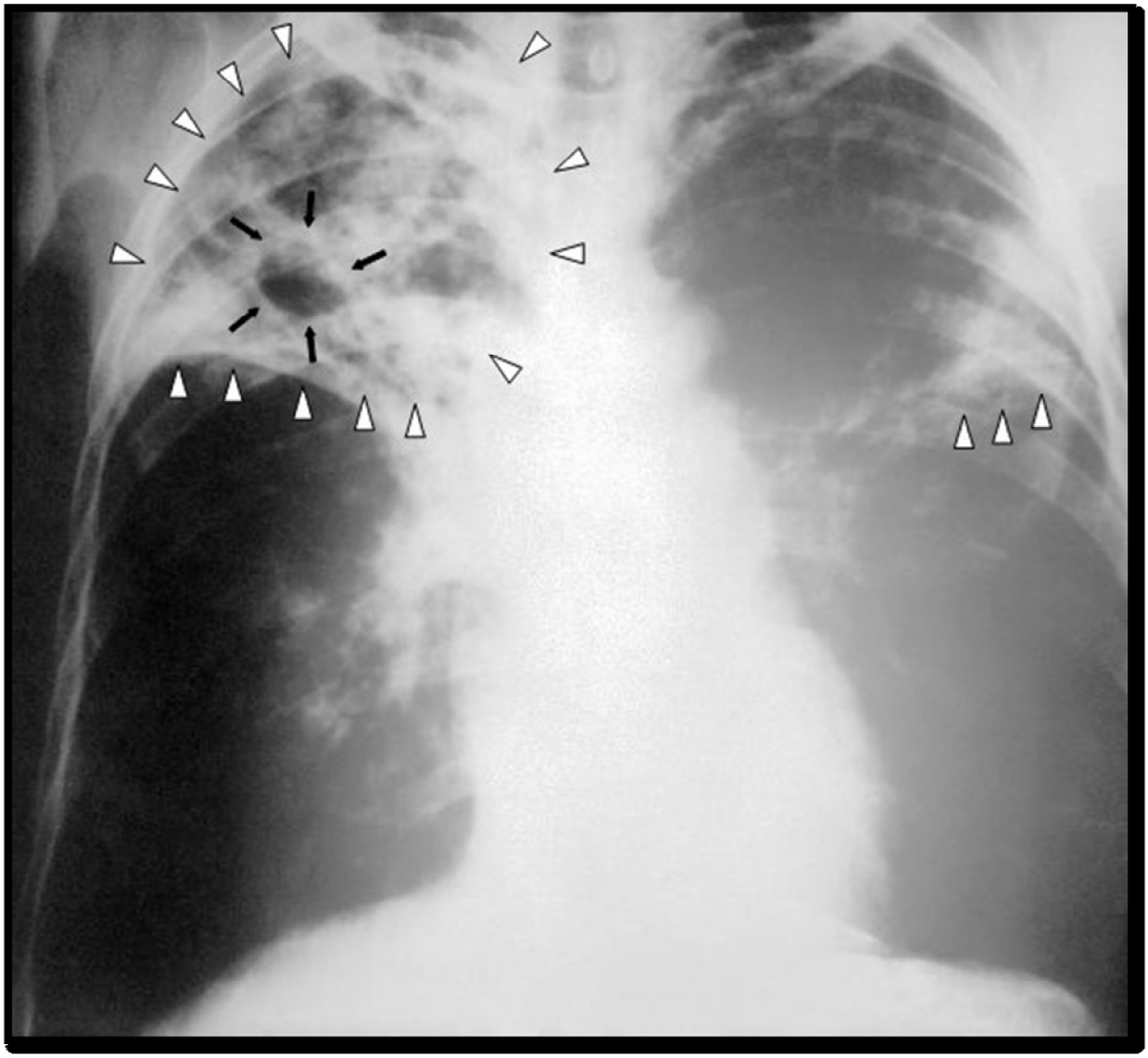

Discussion

A high index of suspicion for Pulmonary TB as an etiology of respiratory infections in cancer patients should always be maintained. Nosocomial infection, reactivation or BCG vaccine in cases of bladder carcinoma is few of the possibilities that should be entertained in our scenario. A case report from Arkansas, United States has discussed nosocomial transmission of *Mycobacterium bovis* Bacille Calmette-Guerin to children receiving cancer therapy and to their health care providers (Norman, 2000). Reactivation of BCG vaccine in patients receiving cancer chemotherapy is

one of the probable differentials in our case in addition to the more likely possibility of a nosocomial infection Various cases have been reported worldwide on how tuberculosis has occurred post chemotherapy or radiation therapy in cancer patients (Zivanovic, 2010).

In the Indian scenario two large tertiary centre studies have been conducted (Kamble, 2006; Singh, 2013). Both the studies have successfully demonstrated that the incidence of pulmonary tuberculosis in cancer chemotherapy is quite high if proper preventive measures are not adequately utilised. In our case the importance of hospital planning and isolation of the wards on the basis of risk stratification of patients according to their susceptibilities for nosocomial spread of deadly infections also comes in to play as the very close proximity of the wards also might have played a role in catalysing the spread in already immunocompromised patients. Steps to recognise and prevent spread of this disease in cancer patients need frequent review and a special section of the guidelines on prevention of hospital acquired infections in each hospital needs to be dedicated on addressing this issue (Biswal, 2013). The role of measures like adherence to universal precautions, targeted empirical therapies and optimal diagnosis, management and timely follow up cannot be overemphasised.

In Conclusion, timely prevention and early recognition of hospital acquired infections especially pulmonary TB may reduce both morbidity and mortality in already immunocompromised cancer patients.

References

Biswal, S. 2013. Incidence and management of infections in patients with acute leukemia following chemotherapy in general wards. *ecancer*, **7**: 310 doi: 10.3332/ecancer.2013.310.

Ducel, G. 2012. Prevention of hospital-acquired infections: A practical guide, 2nd edn, WHO/CDS/CSR/EPH/2002.12.

Kamble, R.M. 2006. Simultaneous presentation of pulmonary tuberculosis and lung cancer: experience from a regional cancer centre. *Indian J. Med. Paediatr. Oncol.*, 27(3).

Norman, J. Waecker, Jr. 2000. Nosocomial transmission of *Mycobacterium bovis* Bacille Calmette-Guerin to children receiving cancer therapy and to their health care providers. *Clin. Infect. Dis.*, 30: 356–62.

Singh, N. 2013. Pleuropulmonary tuberculosis following chemotherapy for lung cancer at a tertiary care centre in India. *J. Postgrad. Med. Edu. Res.*, 47(4): 177–180.

Teresa, R. Zembower, 2014. Epidemiology of infections in cancer patients. *Cancer Treat. Res.*, 161. doi: 10.1007/978-3-319-04220-6_2.

Zivanovic, S. 2010. A case of acute tuberculous pleuropneumonia in a patient with acute lymphoblastic leukemia. *Sci. World J.*, 10: 578–585.